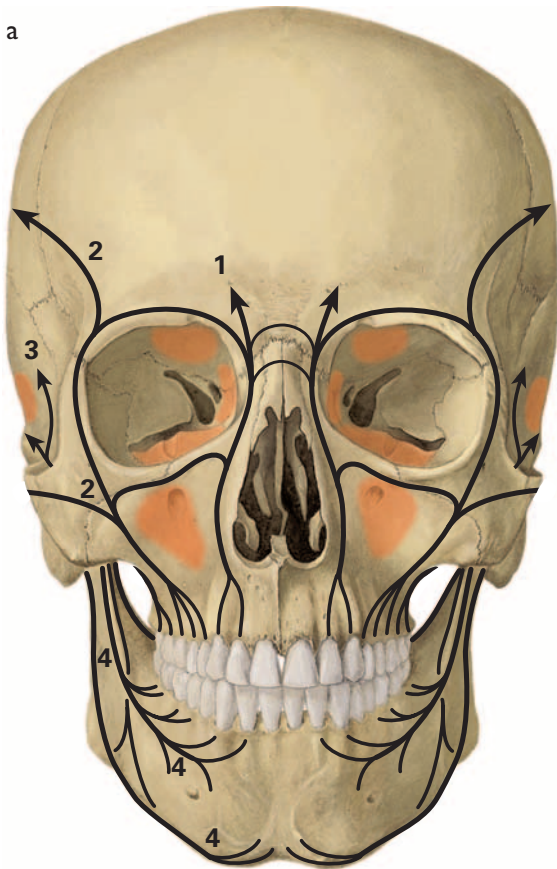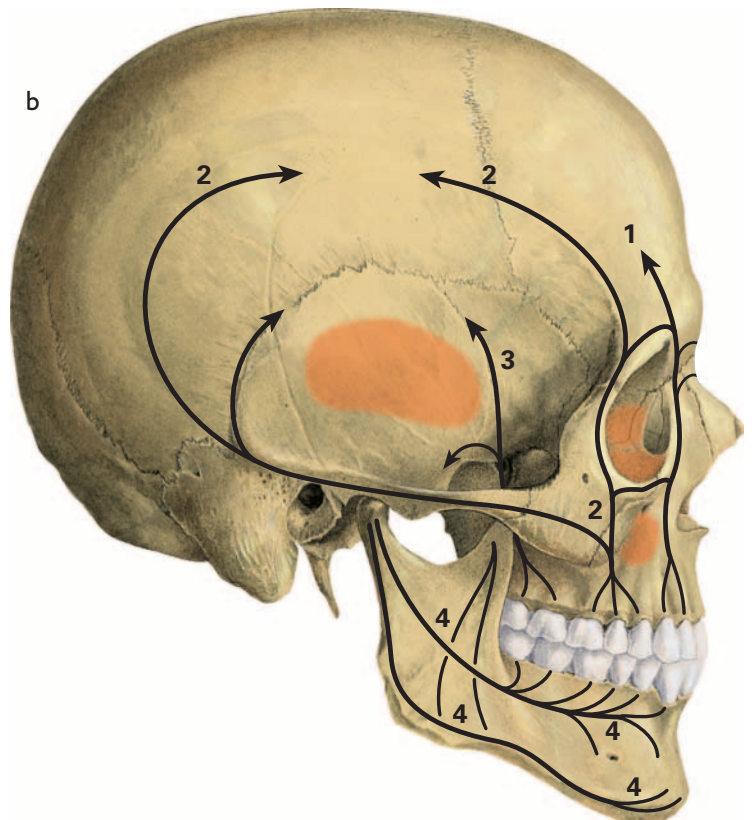


- 1 Canine pillar
- 2 Zygomatic pillar
(anterior and posterior divisions)
- 3 Pterygoid pillar
- 4 Mandibular trajectories



52 Viscerocranium = Facial skeleton (50%)

Pillars of thickened bone material (= trajectories) of the facial skeleton (black lines and arrows) and areas of very thin bone substance (orange areas)

a Ventral aspect

b Right lateral aspect